Lateral Process Fracture of the Talus: A Case Series and Review of the Literature

Wijers, Olivier; Posthuma, Jelle J.; de Haas, Mathijs B. J.; Halm, Jens A.; Schepers, Tim

Published in:
Journal of foot and ankle surgery

DOI:
10.1053/j.jfas.2019.02.003

Published: 01/01/2020

Document Version
Peer reviewed version

Citation for pulished version (APA):
Wijers, O., Posthuma, J. J., de Haas, M. B. J., Halm, J. A., & Schepers, T. (2020). Lateral Process Fracture of the Talus: A Case Series and Review of the Literature. *Journal of foot and ankle surgery*, *59*(1), 136-141. https://doi.org/10.1053/j.jfas.2019.02.003

Elsevier Editorial System(tm) for The Journal of Foot and Ankle Surgery
Manuscript Draft

Manuscript Number: JFAS-18-550

Title: Lateral process fracture of the talus: A case series and review of the literature

Article Type: Case Reports and Series (N < 30)

Section/Category: Trauma

Keywords: Lateral talar fracture; Snowboarders fracture; Ankle injuries; Talus; Trauma

Corresponding Author: Dr. Jelle Posthuma,

Corresponding Author's Institution:

First Author: Olivier Wijers, MD, PhD

Order of Authors: Olivier Wijers, MD, PhD; Jelle Posthuma, MD, PhD; M B de Haas, MD, PhD; Jens A Halm, MD, PhD; Tim Schepers, MD, PhD

Abstract: Background: Fracture of the lateral process of the talus (LPFT) is a frequently overlooked injury, which can lead to severe complaints if not treated adequately. The aim of this study was to evaluate treatment and long-term outcomes of LPFT, with an overview of the literature. Furthermore, we propose a modified classification based on severity and intra- or extra-articular location of LPFT. Methods: Patients diagnosed with LPFT and treated at a Level 1 trauma center between 2001 and 2018 were included. Fracture and treatment characteristics were recorded in combination with functional outcome and quality of life after a mean follow-up of 5.5 years (range 0.8 - 17.2). A comprehensive literature search was performed to identify all case series regarding patients with LPFT. Results: Thirty-six patients were included. According to our modified classification 1 patient had type 1A (2.8%); 6 patients type 1B (16.7%); 10 patients type 2 (27.8%); 11 patients type 3 (30.6%); 6 patients type 4A (16.7%); 2 patients type 4B (5.6%). Twenty eight patients underwent operative fixation (78%). The median AOFAS hindfoot score was 75 (range 12 - 100). The median Foot Function Index was 2 (range 0 - 9). The median score for the EQ-5D was 0.8 (range -0.5 - 1) and median score for health status component was 75 (range 30 - 98). Conclusion: There is some room for conservative treatment of LPFT, however we strongly believe that this should only be considered in undisplaced, small fragment, and extraarticular fractures. Surgical treatment leads to overall good (long-term) outcome.

Cover Letter

To the Editor

The Journal of Foot & Ankle Surgery

Dear Dr. D. Scot Malay,

Hereby we would like to submit the enclosed manuscript, entitled “Functional outcome following bridge plating in Lisfranc injuries” for consideration in your journal.

All authors have contributed to the writing, data acquisition and analysis.

None of the authors has a conflict of interest.

On behalf of all authors

Sincerely,

T. Schepers

P.J. van Koperen

Corresponding author:

T. Schepers

Academic Medical Center

Trauma Unit, Department of Surgery

Meibergdreef 9

PO Box 22660

1100 DD Amsterdam

The Netherlands

email: t.schepers@amc.nl

Author's Conflict of Interest Disclosure Form (rev. 09-2010)

***All authors** must complete, execute, and return only this page to The Journal of Foot & Ankle Surgery.*

Manuscript Number and Title: Lateral process fracture of the talus: A case series and review of the literature

Authors (please print): O. Wijers, JJ. Posthuma, MBJ de Haas, JA Halm, T Schepers

1. **Attestation of Investigator Independence/Accountability:** Did the authors have full access to all study data, take full responsibility for the accuracy of the data analysis, and have authority over manuscript preparation and decisions to submit the manuscript for publication?
   ☑ **Yes**
   ☐ **No** *(Please describe below and on a separate sheet if necessary.)*

2. **Institutional Conflicts of Interest:** Are you aware that any of the authors' academic institutions or employers has any financial interest in or a financial conflict with the subject matter or materials discussed in this manuscript?
   ☑ **No**
   ☐ **Yes** *(Please describe below and on a separate sheet if necessary.)*

3. **Authors' Financial Conflict of Interest**

Category of Potential Conflict	Authors having any of the Required Disclosures described on page 1 must write the author's name and the dollar amount (if any) of the disclosure in the appropriate "yes" box below. If none of the authors has a listed relationship, check the appropriate "no" box. Provide explanations on a separate sheet, and insert a disclosure statement in the manuscript. Please consider the last 2 years through the next 12 months when answering this question. Please update this form any time after submitting your manuscript and prior to publication, if the information changes.	
	No	**Yes**
A. Leadership Position	✓	
B. Consultant/Advisory Role	✓	
C. Stock Ownership	✓	
D. Honoraria	✓	
E. Research Funding	✓	
F. Expert Testimony	✓	
G. Other Compensation	✓	

As corresponding author, I attest that the information on this form is true:

Name (please type or print) Tim Schepers

Signature T. Schepers Date: 12-20-2018

(Please use additional copies of this form for coauthors, if necessary. Mail to: Editor, JFAS, 2314 Waverly Street, Philadelphia, PA 19146; or fax (eFax) to **215-405-3974**; or email scanned forms to: editorjfas@gmail.com. **Return only this final page**. Do not return the preceding explanatory page. Thank you.)

Lateral process fracture of the talus: A case series and review of the literature

Wijers O[1], Posthuma JJ[1], De Haas MBJ[1], Halm JA[1], Schepers T[1]

[1] Trauma Unit, Amsterdam University Medical Center, location AMC, Amsterdam, The Netherlands

Corresponding author:

dr. Tim Schepers

Trauma Unit

Amsterdam UMC

Amsterdam Movement Sciences

Meibergdreef 9

1105 AZ

Amsterdam

The Netherlands

E: t.schepers@amc.nl

Lateral process fracture of the talus: A case series and review of the literature

ABSTRACT:

Background: Fracture of the lateral process of the talus (LPFT) is a frequently overlooked injury, which can lead to severe complaints if not treated adequately. The aim of this study was to evaluate treatment and long-term outcomes of LPFT, with an overview of the literature. Furthermore, we propose a modified classification based on severity and intra- or extra-articular location of LPFT. Methods: Patients diagnosed with LPFT and treated at a Level 1 trauma center between 2001 and 2018 were included. Fracture and treatment characteristics were recorded in combination with functional outcome and quality of life after a mean follow-up of 5.5 years (range 0.8 – 17.2). A comprehensive literature search was performed to identify all case series regarding patients with LPFT. Results: Thirty-six patients were included. According to our modified classification 1 patient had type 1A (2.8%); 6 patients type 1B (16.7%); 10 patients type 2 (27.8%); 11 patients type 3 (30.6%); 6 patients type 4A (16.7%); 2 patients type 4B (5.6%). Twenty eight patients underwent operative fixation (78%). The median AOFAS hindfoot score was 75 (range 12 - 100). The median Foot Function Index was 2 (range 0 – 9). The median score for the EQ-5D was 0.8 (range -0.5 – 1) and median score for health status component was 75 (range 30 – 98). Conclusion: There is some room for conservative treatment of LPFT, however we strongly believe that this should only be considered in undisplaced, small fragment, and extraarticular fractures. Surgical treatment leads to overall good (long-term) outcome.

LEVEL OF EVIDENCE IV

KEYWORDS: Lateral talar fracture; Snowboarders fracture; Ankle injuries; Talus; Trauma;

INTRODUCTION

Lateral process fracture of the talus (LPFT) was firstly described in 1943 by Marotolli, followed by Bonnin in 1950.[2,13] LPFT is a rare condition, with an incidence of less than 1% of all fractures and less than 10% of all foot fractures.[22] Furthermore, considering all talar fractures, LPFT accounts for 10-25%.[10] Not surprisingly, LPFT is infrequently described in the literature, with less than 200 cases since 1943. Its functions include lateral stabilization of the ankle with help from the lateral talocalcaneal ligament, articulation with the fibula and subtalar motion. LPFT is often described in snowboarders and following high-energy trauma. It is commonly thought to be caused by forced dorsiflexion and inversion of the ankle. However, several other biomechanical mechanisms, such as eversion, axial impaction, and exorotation, have been described.[3,6,17] The symptoms of a LPFT resemble the symptoms of an ankle sprain and are, therefore, easily overlooked. Usually, radiographic workup involves X-ray imaging with mortise and lateral views of the foot. Lateral views of normal ankles demonstrate a V-shaped lateral talar process, which might be disrupted in LPFT. However, sensitivity and specificity of a disrupted V-sign in LPFT is only 77% and 59%, respectively.[9] This leads to a high rate of misdiagnosis in LPFT up to 33 to 41%.[8,16] This may cause considerable delay in treatment, associated with increased morbidity due to malunion, non-union, and/or osteoarthritis.

The Hawkins classification for LPFT is based on the severity of the fracture.[8] This classification has since then seen several revisions. [1,14] Due to the low incidence of LPFT long-term outcomes are lacking to optimize treatment.[20] Therefore, the aim of the study was to evaluate treatment and the long-term outcomes of LPFT treated in a Level 1 trauma center with a review of the literature.

PATIENTS AND METHODS

Case series

We present our experience with trauma patients with LPFT who were treated at our Level 1 trauma center between 2001 and 2018. Institutional review board approval and informed consent was obtained. Patients were identified in the electronic hospital database using the billing code (DBC) 0303;241 and operation code 338733.

Patient, fracture and treatment characteristics were collected from the electronic hospital database and the picture archiving and communication system (PACS). Patient characteristics: age at trauma, gender, medical history, smoking and the use of alcohol. Fracture characteristics recorded included mechanism of trauma, side of fracture, concomitant ipsi- or contralateral lower extremity injuries and type of fracture based on plain radiographs and CT scan. For the classification of the LPFT we modified the most recent classification for LPFT by Boack et al. based on the severity, intra- or extraarticular location of the fracture, and the possible joint dislocation ranging from type 1A to 4B (Fig. 1).[1] Our modified classification focus solely on the lateral process fractures with possible joint dislocation and instability whereas Boack et al. describes both lateral and posterior processes.

Treatment characteristics extracted from records included type of treatment, complications (operational site infection and secondary fusion) and need for implant removal. Functional outcome was assessed using the Foot Function Index (FFI, best score 0 points), and the American Orthopaedic Foot and Ankle Society hindfoot score (AOFAS, best score 100 points) The AOFAS score was divided into groups according to the literature: a score of 90–100 was graded as an excellent result; 75–89 as good; 50–74 as fair, and less than 49 points was graded as a failure or poor outcome. Quality of life (QOL) was measured by the EuroQol-5D (EQ-5D) which consists of a descriptive system and the EQ Visual Analogue Scale (EQ VAS). The descriptive system comprises five dimensions: mobility, self-care, usual activities, pain/discomfort and anxiety/depression. The EQ VAS is an assessment of perceived general health on a scale of zero to 100, in which 100 represented excellent

general health. Patient satisfaction was also measured using the VAS of zero to 10, in which 10 represents the best possible satisfaction.

Statistical analysis

The statistical analysis was performed using the Statistical Package for the Social Sciences (SPSS) version 24 (SPSS, Chicago, IL). Numeric data is expressed with medians and categorical data are shown as numbers with percentages.

Literature search

A literature search was performed to identify all case series regarding patients with LPFT. The electronic database up to July 1st, 2018 of the Cochrane Library, Pubmed Medline, EMbase, and Google Scholar were explored using the combination of the following search terms and Boolean operators: Talus OR Talar OR Snowboarder AND Lateral process OR Peripheral AND Fracture*. All studies after 2000 regarding patients with LPFT were included, if they treated more than 1 patient (case series), treated adult patients, and were in English writing. Additionally, a comprehensive search of all the reference lists was conducted to identify related studies. Number of included patients, fracture characteristics, treatment, outcome and complications were extracted from these publications.

RESULTS

Demographics

Thirty-eight patients were identified between 2001 and 2018 with a LPFT. One patient did not consent to the study and in one patient electronic data was incomplete. The median follow up was 5.5 years, (range 1–17.2). Of the remaining 36 patients 13 were female (36%) with a median age of 35 years at the time of injury (range 15-64). The trauma mechanism most

commonly seen was a fall from height in 11 patients (30%). Six patients fell during daily activities (17%), eight patients due to a motor vehicle accident (22%), five patients due to a direct blunt trauma (14%), five patients during sport (14%) and in 1 patient the trauma mechanism was not clear. Fifteen patients (42%) had an isolated injury of the talus, whereas 21 patients (58%) had concomitant lower extremity injuries. Fifteen of these were ipsilateral (calcaneus n=10, medial malleolus n=1, pilon n=1, metatarsal n=1, cuboid n=1, femur n=1) and 10 were contralateral (calcaneus n=2, talus n=5, pilon n=2, femur n=1). In 15 patients, solely the lateral process was fractured. Other concomitant fractures of the ipsilateral talus included posterior process n=7, corpus n=2, neck n=9, head n=1). Fracture- and patient characteristics are shown in Table 1.

In 8 patients (22%) the talus fracture was treated conservatively. In 28 patients, an operation was performed including open reduction and internal fixation (ORIF) n=26 (72%) and primary arthrodesis n=2 (6%). In three polytrauma patients the fracture was severely comminuted or dislocated, requiring an external fixator for initial stabilization. One patient underwent a closed reduction of the dislocated talus at the emergency department.

Functional outcome, treatment satisfaction and quality of life

A total of 18 patients (50%) returned the validated questionnaires. The median AOFAS hindfoot score for this group was 75 (range 12-100) points. 3 patients with an excellent result, 8 patients with a good result, 5 patients with a fair result and 2 patients with a poor outcome. The median Foot Function Index was 2 (range 0–9) points. Overall, patients scored a median of 9 points (range 5–10) on treatment satisfaction. The median score for the EQ-5D was 0.8 (range -0.5–1) and median score for health status component was 75 (range 30–98).

Literature search

A total of 95 articles were identified, of which 71 were excluded (Fig. 2). Of the 24 included articles, 3 case series where found (range 1-44 patients per article). In addition to this, 4 case series where included based on scanning reference lists (Fig. 2, Table 2). In general, displaced fractures were treated operatively, where nondisplaced fractures were mainly treated nonoperatively.[17,19] Complication rate ranged from 4% to 45%; including osteoarthritis (15% to 38%), non-union (4% to 39%) and secondary arthrodesis (10% to 15%).[8,14,16,17,21] Not surprisingly, non-union has been reported to a much higher extend in displaced LPFT managed nonoperatively (60%), when comparing to (early) operative fixation (5%). In addition to this, delayed diagnosis was observed in 14% to 70%. Functional outcome was mainly scored according to the AOFAS and ranging from 85 to 95 points.[11,12,21,24]

DISCUSSION

Our study shows that in patients with LPFT, the outcome is generally good, when treated mainly operatively. Only small fragment and extra-articular fractures should be treated nonoperative, which is supported by the literature review.

When reviewing the literature guidelines for the treatment of LPFT are lacking. Therefore, we aimed to provide more insight in the long-term outcomes after treatment of a LPFT, by evaluating a large series of 36 patients. Only one other article described a larger serie of 44 cases.[21] This study had a mean follow-up of 17 months and also used the AOFAS score to evaluate the outcome. The overall results for the total patient group at the last follow up was in 52% excellent, 23% good, 21% fair and in 2% poor. Better results were seen in patients who were treated immediately after the trauma versus patients with a delayed diagnosis. In our study the overall results were excellent in 17%, good in 44%, fair in 28% and poor in 11%. Only 44% of the cases in their group had associated lesions versus 58% in our patient group. This could be a possible explanation for the differences in outcome. The indication for operative treatment was not described, but because a large percentage underwent

secondary and even tertiary surgery they conclude that a broader indication for surgery as initially treatment is in place. To treat LPFT adequately, good diagnostics are essential. Whisby et al. and Ebraheim et al. advocated that CT-scan is effective in assessing the size and displacement of the fragment.[5,25] Therefore, in patients with a typical clinical presentation (pain and swelling of the ankle with local tenderness anterior to the tip of the lateral malleolus), a CT scan should be considered[14,18]. In some cases, the fracture can be seen on plain radiographs. A symmetrical V shaped contour can be seen on a lateral view in patients with an intact lateral process, where in patients with LPFT this V shape is out of balance and asymmetrical. In case of any doubt a CT scan is recommended.[9] MR imaging was not part of our acute diagnostic work-up however in case of persisting complaints or for evaluation of ligamentous injury an additional magnetic resonance imaging (MRI) scan was obtained.

Only 42% of our patients had an isolated fracture of the lateral process. The majority had concomitant ipsilateral and/or contralateral injuries of the lower extremity. This is in contrast of what is described by Tinner et al. who reports that LTPFs are mostly isolated fractures.[23] Furthermore they describe additional ipsilateral fractures of the talus in 10%. This was in our patient group 50%. A possible explanation is that our study group mostly consist of polytrauma patients that were seen in a Level 1 trauma center. It also underlines the importance of intensive imaging.

Hawkins Type I fractures (small fragment) (42%) are more common than type II (comminuted) (32%) and type III (chip fracture) (24%).[20] McCory and Bladin describe LPFT as Type I for the chip fracture, Type II for the small fragment, and Type III as the comminuted fractures.[14] Subsequently, Funk et al. tried to improve the classification of LPFT, by differentiating fractures in more detail. This classification however was intended for experimental studies and has not been adopted in the clinical setting.[7] Subtalar injuries are a continuum of different injuries. We encountered a few combined injuries of LPFT and sustentaculum tali. We think these are a pre-stage of a full-blown subtalar or peritalar dislocation. We were unable to find any similar injuries in the literature. Our modified

classification is solely focused on LPFT and is based on the severity, intra- or extraarticular location of the fracture and possible joint dislocation ranging from type 1A to 4B (Fig. 1). We think this is a more complete and logical classification of LPFT.

Fall from height was the leading cause in our study for LPFT followed by fall during daily activities. The exact biomechanical mechanism causing these injuries is not clear and still a point of discussion. Cimmino et al. advocated involvement of three forces: direct axial force; forced supination of the ankle; and direct external force.[4] In contrast to this, Hawkins described that the lateral talocalcaneal ligament is not strong enough to cause an avulsion fracture. Hawkins took the movements of the foot into consideration and concluded that external force from the calcaneus to the lateral process causes the fracture when the ankle is inverted and dorsiflexion force is applied to it.[8] Fjeldborg et al. stated that when the foot is inverted the lateral process becomes the only junctional area between the posterior joint surface and the talus, and that when dorsiflexion force is applied in that position, a fracture occurs because the external force is concentrated on the lateral process.[6] We think that LPFT after high velocity accidents cannot simply be subscribed due to one type of trauma mechanism but is a combination of mechanisms as described above.

Patients with small or intermediate fractures were treated nonoperative in our population by a cast up to 16 weeks (range 0-16). This wide range was mainly due to concomitant fractures at the ipsilateral side for which sometimes longer cast was indicated. Literature recommends for nondisplaced fractures non-weight bearing immobilization for 4-6 weeks followed by a weight bearing cast for an additional 3 weeks.[15,22,23]

In our study, 79% of all patients underwent operative repair. All patients with a type 4A and 4B were treated operatively, including 2 primary arthrodesis. For all other types, most patient underwent surgery (Type 3: 64%, Type 2: 80%, Type 1B: 83%). Comorbidities and a delay in diagnosis were the most important reasons for conservative treatment. In contrast, all type 1A fractures were treated conservative by means of cast immobilization.

Outcomes of LPFT depends on early recognition of the fracture without delay in treatment. Sariali et al. found that osteoarthritis was more common in delayed diagnosed population (46%), when comparing to the early diagnosed population (29%).[21] Moreover, long-term outcome is most dependent on the fracture characteristics. Restoration of anatomically joint surface and limitation of the degree of traumatic cartilage damage is the key for a good outcome. Hawkins showed that conservative treatment of the type II and III fractures resulted in high morbidity, since approximately 50% of the patients with a type II or III fracture treated with cast had complications like chronic pain (46%) and non-union (39%).[8] These findings fit with the commonly accepted consensus that only the small chip fractures can be treated conservatively, whereas large-fragment, intra-articular and comminuted fractures should be treated operatively. Knoch et al. evaluated AOFAS scores after treating 23 patients including Mccrory-bladin type I (one case, conservative); type II (15 cases, 11 operative) and type III (seven cases, five operative), leading to an mean AOFAS score of 94 after 42 months.[11] These results are in line with the outcome as described by Valderrabano et al., which treated the McCrory-Bladin type I conservative and performed operative repair in the McCrory-Bladin type II fractures, leading to a mean AOFAS score of 93 after 3.5 years follow-up, suggesting that nondisplaced type II (large-fragment) fractures may be better treated operatively to decrease future morbidity such as malunion, nonunion, joint stiffness and chronic pain.[24] This was supported by Maes et al., where AOFAS scores where obtained from 7 patients with a McCrory-Bladin type II and III treated operatively by open reposition and internal fixation with removal of small fragments.[12] In that study, the mean AOFAS score was 85 (74 – 100) after 10 years. Comparing these results to our study group, in our population the median AOFAS score was 75. The latter, slightly lower when comparing to the former study, which might be due to a higher percentage of severe and comminuted fractures with in some cases combined with joint dislocation in our group.

With a median follow up of 5,5 years we found one wound infection after surgery and in 11 cases the implant was removed due to complaints. Because of complete destruction of the

joint surface with cartilage damage an arthrodesis was performed in 2 patients respectively 14 and 34 months after the initial operation. Our results resembles with the outcome of other studies where a wide range of complications is described.[17,21].

A limitation of this study is the high rate of concurrent injuries what undisputedly effects the choice of treatment and the overall outcome. Next to this we must acknowledge the possibility of underreporting simple extra-articular fractures, type 1A, because they are easily overlooked.

CONCLUSION

LPFT can lead to severe complaints when not treated on time and adequately. Therefore, caution should be warranted of anterolateral ankle pain (below malleolus) during inversion and dorsiflexion. Given the low sensitivity and specificity of conventional X-ray imaging, CT-scan should be considered in these patients. There is some room for conservative treatment of LPFT, however we strongly believe that this could only be considered in small fragment and extraarticular fractures. In addition to this, operative treatment should be the first choice in large fragment, intra-articular, and/or comminuted LPFT, due to the better (long-term) outcome and lower complication rate.

REFERENCES

1. Boack DH, Manegold S. Peripheral talar fractures. *Injury*. 2004;35:23-35. doi:10.1016/j.injury.2004.07.019.

2. Bonnin G. Injuries to the ankle. 1950.

3. Boon AJ, Smith J, Zobitz ME, Amrami KM. Snowboarder ' s Talus Fracture Mechanism of Injury. *Sport Med*. 2001;29(3):333-338.

4. Cimmino C. Fracture of the lateral process of the talus. *Am J Roentgenol Radium Ther Nucl Med*. 1963;Dec;90:1277-1280.

5. Ebraheim N, Skie M, Podeszwa D, Jackson W. Evaluation of process fractures of the talus using computed tomography. 1994:Aug;8(4):332-7.

6. Fjeldborg O. Fracture of the Lateral Process of the Talus: Supination-Dorsal Flexion Fracture. *Acta Orthop Scand*. 1968;6470:39(3):407-12. doi:10.3109/17453676808989476.

7. Funk JR, Srinivasan SCM, Glas F, Crandall JR. Snowboarder ' s Talus Fractures Experimentally Produced by Eversion and Dorsiflexion. *Am J Sport Med*. 2003;31(6):921-928.

8. Hawkins LG. Fracture of the Lateral Process of the Talus: A review of thirteen cases. *J Bone Jt Surg Am*. 1965;Sep;47:1170-1175.

9. Jentzsch T, Hasler A, Renner N, et al. The V sign in lateral talar process fractures : an experimental study using a foot and ankle model. *BMC Musculoskelet Disord*. 2017:1-7. doi:10.1186/s12891-017-1642-x.

10. Kirkpatrick DP, Hunter RE, Janes PC, Mastrangelo J, Nicholas RA. The Snowboarder ' s foot and ankle. *Am J Sport Med*. 1998;26(2):271-277.

11. Knoch F Von, Knoch M Von. Foot and Ankle Fracture of the lateral process of the talus in snowboarders. *J Bone Jt Surg Br*. 2001:772-777. doi:10.1302/0301-620X.89B6.18813.

12. Maes R, Delmi M, Dojcinovic S, Peter R, Hoffmeyer P. Fractures of the lateral process of the talus. A report of seven operated cases. *Foot Ankle Surg*. 2004;10:131-133. doi:10.1016/j.fas.2004.04.003.

13. Marotolli O. Sobre las fracturas de la apofisis externa del astragalo. 1943:13:107-17.

14. McCrory P, Bladin C. Fractures of the lateral process of the talus: a clinical review. “Snowboarder’s ankle”. *Clin J Sport Med*. 1996:Apr;6(2):124-8.

15. Miller S. Fractures of the lateral process of the talus: Snowboarder’s Fracture. *Foot*. 1996;6(4):188-192. doi:10.1016/S0958-2592(96)90021-8.

16. Mills HJ. Fractures of the lateral process of the talus. *Aust N Z J Surg*. 1987:643-646.

17. Mukherjee SK, Glasgow R, Andrew P, Division S, Infirmary G. Fracture of the lateral process of the talus. A report of thirteen cases. *J Bone Jt Surg Br*. 1974;2(May).

18. Nicholas R, Hadley J, Paul C, Janes P. Snowboarder ’ s Fracture: Fracture Of The Lateral Process Of The Talus. *J Am Board Fam Pr*. 1994;7(2):130-133.

19. Parsons S. Relation between the occurrence of bony union and outcome for fractures of the lateral process of the talus: a case report and analysis of published reports. *Br J Sport Med*. 2003:274-276.

20. Perera FA, Baker MJF, Lui MDF, Stephens FMM. The management and outcome of lateral process fracture of the talus. *Foot Ankle Surg*. 2010;16(1):15-20. doi:10.1016/j.fas.2009.03.004.

21. Sariali E, Lelièvre J, Catonné Y. Fractures of the lateral process of the talus. Retrospective study of 44 cases. *Rev Chir Orthop Reparatrice Appar Mot*. 2008:1-7.

doi:10.1016/j.rco.2008.04.009.

22. Summers NJ, Murdoch MM. Fractures of the Talus: A Comprehensive Review. *Clin Pod Med Surg*. 2018;29(2012):187-203. doi:10.1016/j.cpm.2012.01.005.

23. Tinner C, Sommer C. Fractures of the Lateral Process of the Talus. *Foot Ankle Clin NA*. 2018;23(3):375-395. doi:10.1016/j.fcl.2018.04.009.

24. Valderrabano V, Perren T, Ryf C, Rillmann P. Snowboarder ' s Talus Fracture Treatment Outcome of 20 Cases After 3.5 Years. *Am J Sport Med*. 2005:871-880. doi:10.1177/0363546504271001.

25. Whitby E, Barrington N. Fractures of the lateral process of the talus—the value of lateral tomography. *Br J Radiol*. 1995;68(810):583-586.

Tables:

Table 1 Fracture, treatment and complication characteristics

Fracture Side	Left	N = 12 (33 %)
	Right	N = 19 (53 %)
	Both	N = 5 (14 %)
Open fracture	Yes	N = 2 (6 %)
	No	N = 34 (94%)
Type of fracture (modified classification)	Type 1A: Small fragment extraarticular	N = 1 (3%)
	Type 1B: Small fragment intraarticular	N = 6 (17%)
	Type 2: Intermediate fragment intraarticular	N = 10 (28%)
	Type 3: Comminuted or severe fracture intraarticular	N = 11 (31%)
	Type 4A: LPFT combined with a sustentaculum tali fracture of the calcaneus without joint dislocation	N = 6 (17%)
	Type 4B: LPFT combined with subtalar or peritalar dislocation	N = 2 (6%)
Preceding operation	Fix ex	N = 3 (8 %)
	Closed reduction	N = 1 (3 %)

Type of surgery		
	ORIF	N = 26 (72 %)
	PA	N = 2 (6 %)
Complications		
	Infection	N = 1 (3 %)
	Implant Removal	N = 11 (31 %)
	Implant Removal + arthrodese	N = 2 (6 %)

Abbreviations: ORIF: Open reduction internal fixation; PA: primary arthrodesis; Fix ex: Fixator external

Table 2 Literature search

Author	n	Year	M/F	Mean age	Type (n)	Treatment (n)	Complications	Outcome	Follow up (months)
Hawkins et al.	13	1965	26/0	26	I: 2 II: 6 III: 5	Type I: 2x Conservative Type II: 6x Conservative Type III: 5x Conservative	Chronic pain 46% Malunion 8% Non-union 39% Osteophytes 15%	ROM and pain	26
Inokuchi et al.	13	1996	23/39	37	?	8x Conservative 5x Operative	Osteoarthritis (after conservative treatment) 15%	Consolidation on X-ray imaging	unknown
Maes et al.	7	2004	33/0	33	II: 4 III: 3	Type II: 2x ORIF and removal of small fragment 2x ORIF Type III: 2x ORIF	Osteoarthritis 29% Delayed diagnosis 14% (10 months) Wound infection 14%	AOFAS Consolidation on X-ray imaging	72

						1x osteotomy (delayed diag)			
Sariali et al.	43	2008	25/8	33	I: 25 II: 5 III: 14	12x 45d foot cast non-weight bearing 2x operative screw fixation	Delayed diagnosis 70% (mean: 46months) Osteoarthritis 46% (delayed diagnosis group) Osteoarthritis 29% (direct diagnosis group) Wound infection 2% (Associated lesions 44%)		17
Valderrabano et al.	20	2010	18/11	29	I: 3 II: 16 III: 1	Type I: 3x conservative Type II: 2x conservative 14x operative III: 1x Conservative	Secondary operative (type II and III) due to debridement 15%	AOFAS	42
Von Knoch et al.	23	2007	28/3	31	I: 1 II: 15 III: 7	Type I: 1x Conservative Type II: 4x Conservative 11x Operative	Malunion 4% (in conservative group) Osteoarthritis 45% (operative group) Associated injuries 88%	AOFAS	42

						ORIF III: 2x Conservative 5x Operative ORIF			
Mukherjee et al.	13	1974	26/11	37	?	Operative Conservative	Arthrosis 38% Delayed diagnosis 54%		20

ROM = Range of motion, AOFAS: American Orthopedic Foot and Ankle Score

Figure 1
Click here to download Figure: Figure 1.pdf

Figures:

Figure 1: Modified classification for LPFT

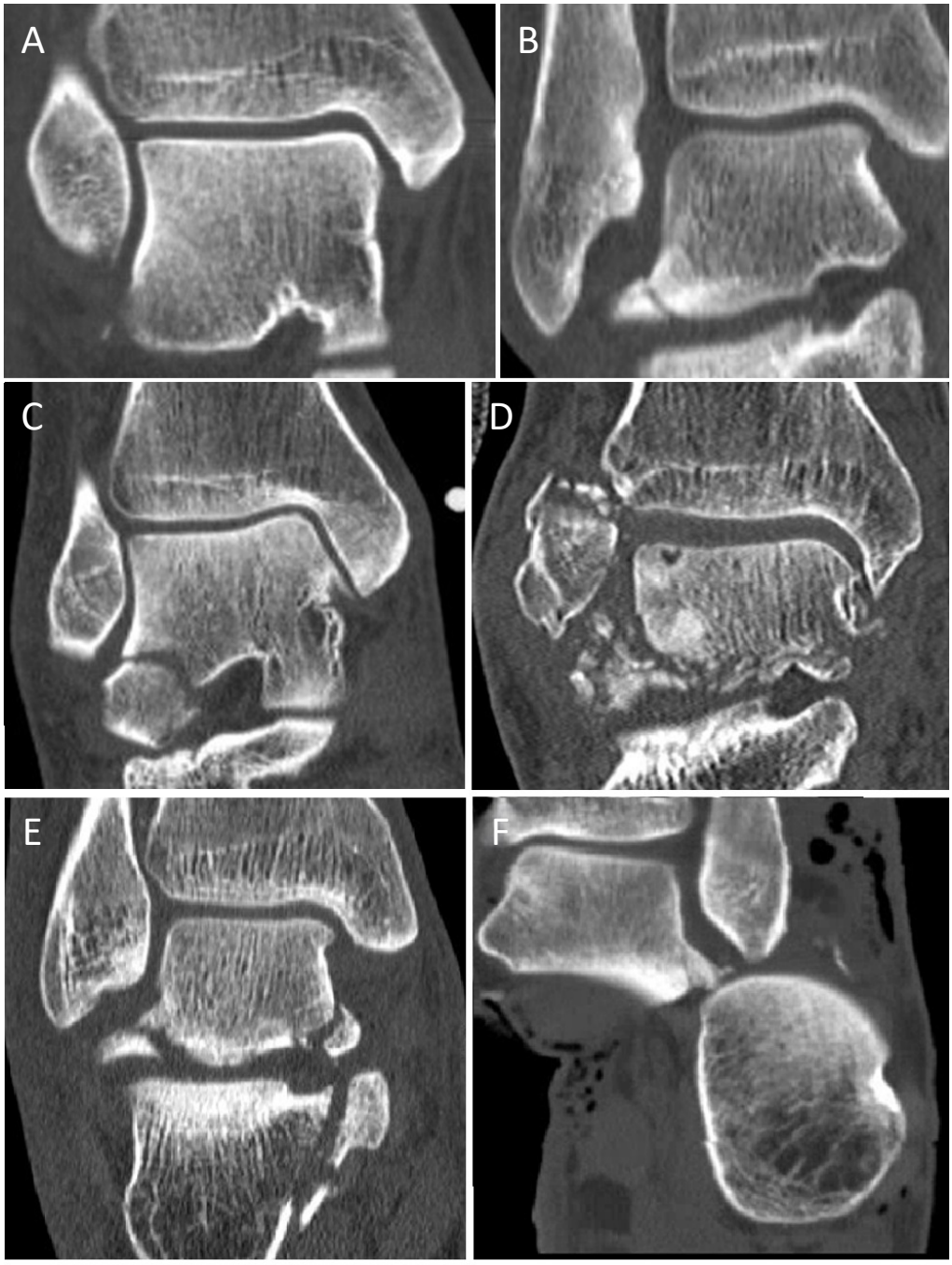

A: Type 1A: CT scan coronal view; Small fragment extraarticular. B: Type 1B: CT scan coronal view; Small fragment intraarticular. C: Type 2: CT scan coronal view; Intermediate fragment intraarticular. D: Type 3: CT scan coronal view; Comminuted or severe fracture intraarticular. E: Type 4A: CT scan coronal view; LPFT combined with a sustentaculum tali fracture of the calcaneus without joint dislocation. F: Type 4B: CT scan sagittal view; LPFT combined with total subtalar dislocation.

Figure 2
Click here to download Figure: Figure 2.pdf

Figure 2. Flowchart of selection process from initial search to inclusion.