

## Pure-AMC

### Two Cases of Endocarditis After MitraClip Procedure Necessitating Surgical Mitral Valve Replacement

Hermanns, Henning; Wiegerinck, Esther M. A.; Lagrand, Wim K.; Baan, Jan; Cocchieri, Riccardo; Kaya, Abdullah

*Published in:*  
Annals of thoracic surgery

*DOI:*  
[10.1016/j.athoracsur.2018.06.019](https://doi.org/10.1016/j.athoracsur.2018.06.019)

Published: 01/01/2019

#### *Document Version*

Version created as part of publication process; publisher's layout; not normally made publicly available

#### *Citation for pulished version (APA):*

Hermanns, H., Wiegerinck, E. M. A., Lagrand, W. K., Baan, J., Cocchieri, R., & Kaya, A. (2019). Two Cases of Endocarditis After MitraClip Procedure Necessitating Surgical Mitral Valve Replacement. *Annals of thoracic surgery*, 107(2), e101-e103. <https://doi.org/10.1016/j.athoracsur.2018.06.019>

#### **General rights**

Copyright and moral rights for the publications made accessible in the public portal are retained by the authors and/or other copyright owners and it is a condition of accessing publications that users recognise and abide by the legal requirements associated with these rights.

- Users may download and print one copy of any publication from the public portal for the purpose of private study or research.
- You may not further distribute the material or use it for any profit-making activity or commercial gain
- You may freely distribute the URL identifying the publication in the public portal ?


#### **Take down policy**

If you believe that this document breaches copyright please contact us providing details, and we will remove access to the work immediately and investigate your claim.

# Accepted Manuscript

Two Cases of Endocarditis after Mitraclip Procedure Necessitating Surgical Mitral Valve Replacement

Henning Hermanns, MD, Esther M.A. Wiegerinck, MD, PhD, Wim K. Lagrand, MD, PhD, Jan Baan, Jr., MD, PhD, Ricardo Cocchieri, MD, Abdullah Kaya, MD, PhD



PII: S0003-4975(18)31001-4

DOI: [10.1016/j.athoracsur.2018.06.019](https://doi.org/10.1016/j.athoracsur.2018.06.019)

Reference: ATS 31772

To appear in: *The Annals of Thoracic Surgery*

Received Date: 17 May 2018

Revised Date: 31 May 2018

Accepted Date: 6 June 2018

Please cite this article as: Hermanns H, Wiegerinck EMA, Lagrand WK, Baan J Jr., Cocchieri R, Kaya A, Two Cases of Endocarditis after Mitraclip Procedure Necessitating Surgical Mitral Valve Replacement, *The Annals of Thoracic Surgery* (2018), doi: 10.1016/j.athoracsur.2018.06.019.

This is a PDF file of an unedited manuscript that has been accepted for publication. As a service to our customers we are providing this early version of the manuscript. The manuscript will undergo copyediting, typesetting, and review of the resulting proof before it is published in its final form. Please note that during the production process errors may be discovered which could affect the content, and all legal disclaimers that apply to the journal pertain.

## **Two Cases of Endocarditis after Mitraclip Procedure Necessitating Surgical Mitral Valve Replacement**

Running Head: endocarditis after MitraClip procedure

Henning Hermanns, MD<sup>1</sup>, Esther M.A. Wiegerinck, MD, PhD<sup>2</sup>, Wim K. Lagrand, MD, PhD<sup>3</sup>,  
Jan Baan Jr., MD, PhD<sup>4</sup>, Ricardo Cocchieri, MD<sup>2</sup>, Abdullah Kaya, MD, PhD<sup>2</sup>

<sup>1</sup> Department of Anesthesiology, Academic Medical Center, University of Amsterdam,  
Meibergdreef 9, 1105 AZ Amsterdam, The Netherlands

<sup>2</sup> Department of Cardiothoracic Surgery, Academic Medical Center, University of Amsterdam,  
Meibergdreef 9, 1105 AZ Amsterdam, The Netherlands

<sup>3</sup> Department of Intensive Care, Academic Medical Center, University of Amsterdam,  
Meibergdreef 9, 1105 AZ Amsterdam, The Netherlands

<sup>4</sup> Department of Cardiology, Academic Medical Center, University of Amsterdam, Meibergdreef 9,  
1105 AZ Amsterdam, The Netherlands

Corresponding author:

Henning Hermanns, M.D.

Academic Medical Center, Amsterdam

Meibergdreef 9, POB 22700

1105 AZ Amsterdam

Email: h.hermanns@amc.uva.nl

**Abstract**

In the present report, we describe two cases of endocarditis following Mitraclip procedures. In both patients, successful bailout surgical treatment was performed despite a high risk constellation due to significant co-morbidities. These cases highlight that surgical treatment may still be an option in patients initially declined for surgical therapy and that endocarditis following Mitraclip procedure might be an under-recognised complication.

MitraClip (Abbott Vascular, Santa Clara, CA, USA) procedure for interventional treatment of mitral valve regurgitation has become increasingly popular worldwide, although sufficient evidence-based consensus recommendations formulating indication criteria are still lacking <sup>1</sup>. Generally, an interdisciplinary heart team approach is recommended and in the majority of cases, MitraClip procedure has been restricted to patients with very high perioperative risk. Having gained FDA approval in 2013, long-term results of the MitraClip procedure are yet to be determined. Short-term complication rate seems acceptable with bleeding complications, pericardial tamponade, cerebrovascular events and clip detachments being the most frequent ones <sup>2</sup>. However, the abundance of often significant comorbidities require rigorous vigilance and team approach for successful treatment and avoidance of complications.

## Case Reports

### *Case 1*

A 76 year old male patient was admitted to our tertiary referral center. He underwent a successful MitraClip procedure for severe eccentric mitral regurgitation (MR) due to prolapse of the posterior leaflet (P2) and tenting of the leaflet. Surgical treatment at that time was declined due to considerable comorbidities (COPD, diabetes mellitus, renal insufficiency). Left ventricular function was severely diminished (LVEF 35%), with a dilated left ventricle. Accordingly, NT-ProBNP was elevated (4207 ng/L). Postprocedurally, mild residual MR was present. The patient recovered uneventfully, and the clinical situation improved.

Two and a half years later, the patient was readmitted to our department with fever of unknown origin and recurrence of shortness of breath. Transthoracic (TTE) and transesophageal echocardiography (TEE) demonstrated a large, bulky vegetation on the posterior leaflet of the mitral valve, accompanied by severe MR (Figure 1). Blood cultures were positive for *Staphylococcus Aureus* – despite meticulous investigations, no causative infectious focus was found. On readmission, an acute on chronic renal failure and de novo atrial fibrillation were present. Despite a high logistic EuroSCORE II of 27.01%, consensus of the multidisciplinary heart

team was surgical mitral valve replacement, considering decline of clinical situation with heart failure and the size of the vegetation (2 cm). Patient was surgically treated with mitral valve replacement (MVR). Intraoperative analysis revealed good insertion of the clip on the anterior leaflet and a large vegetation on the posterior leaflet with a local perforation, through which the clip was partially pulled out the posterior leaflet. The native valve and MitraClip®, which was involved in the endocarditis, were excised en bloc (Figure 2), and replaced by a 31 mm Pericarbon More bioprosthesis (Sorin Group, Burnaby, Canada). Postoperative TEE showed no mitral regurgitation and a mean gradient of 1.5 mmHg. Patient was postoperatively admitted to the ICU, where he was extubated the same day. After an ICU stay of two days, he was discharged to the cardiothoracic surgery ward. Postoperative recovery was complicated by pericardial effusion on postoperative day 14 requiring re-sternotomy as well as by the preexisting renal failure, which temporarily deteriorated under gentamycin therapy for endocarditis. Finally, patient was discharged from hospital 28 days after surgery.

### *Case 2*

A 71-year old man was re-admitted 6 months after successful treatment of severe MR with two MitraClips. At that time, conventional surgery had been declined due to considerable comorbidities (among others severe right ventricular dysfunction, pulmonary hypertension and a giant aneurysm of the circumflex artery). Moreover, patient underwent earlier a CABG procedure as well as Re-Do CABG 10 years later, each followed by re-thoracotomy due to bleeding complications in his medical history. At the time of re-admission, recurrent severe MR as well as severe tricuspid regurgitation were seen on preoperative TTE. Several blood cultures were positive for Staphylococcus Aureus, again no focus for bacteremia was found. Logistic EuroSCORE II was calculated 40.37%, however, multidisciplinary consensus supported surgical treatment. The initial plan was to replace the mitral valve and repair the tricuspid valve via anterolateral approach on fibrillating heart. Yet, due to considerable adhesions, full sternotomy

was performed. At inspection, the mitral valve appeared to be almost completely destroyed. Again, endocarditis involved the MitraClip. Finally, MVR was performed using a 33 mm mechanical valve (St. Jude Medical, Inc, St Paul, MN, USA) followed by a tricuspid valve repair using a Contour 3D 34 mm annuloplasty ring (Medtronic, Minneapolis, MN, USA). Postoperative TEE demonstrated good function of both valves and the patient was transferred to the ICU. ICU stay was complicated by respiratory failure followed by reintubation and eventually tracheostomy as well as circulatory arrest due to right ventricular failure. Finally, after 20 days patient could be discharged to the ward and thereafter to a rehabilitation center.

### **Comment**

Endocarditis has been reported as a very scarce complication after MitraClip procedure <sup>3</sup>. However, quite recently, several cases of MitraClip endocarditis have been reported <sup>4 5</sup>, most of which are followed by surgical mitral valve replacement. Our cases presented here, together with the existing literature, demonstrate that endocarditis after MitraClip procedure might be an underestimated complication. The presented two cases represent ca. 0,5% of all MitraClip procedures performed at our institution. Despite decline at the initial heart team evaluation for mitral valve surgery there is still the possibility of conventional mitral valve surgery as bailout strategy after MitraClip implantation in the hands of an experienced surgical team with favorable outcome despite a high risk constellation. At last, these cases may underline the need for antibiotic prophylaxis for patients with MitraClip in situ, as recommended by the 2015 European Society of Cardiology (ESC) guidelines <sup>6</sup> and the 2017 American Heart Association (AHA) guidelines <sup>7</sup>.

## References

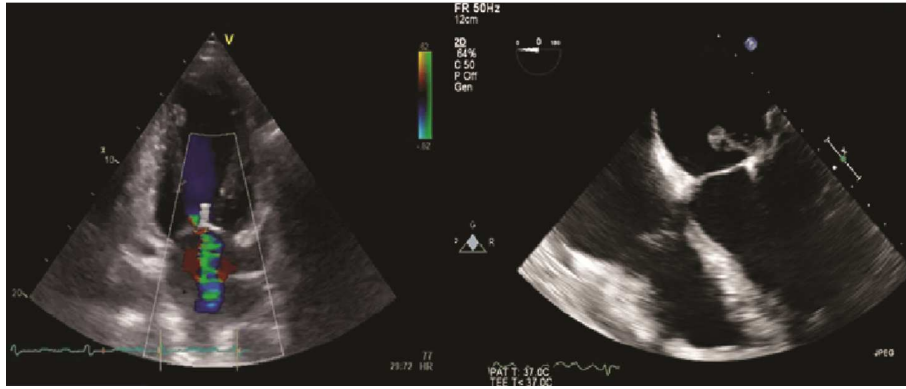
1. Bail DH, Doeblner K. The MitraClip System: a systematic review of indications, procedural requirements, and guidelines. *Thorac Cardiovasc Surg* 2014;62(1):18-25. doi: 10.1055/s-0033-1360509
2. Eggebrecht H, Schelle S, Puls M, et al. Risk and outcomes of complications during and after MitraClip implantation: Experience in 828 patients from the German TRANscatheter mitral valve interventions (TRAMI) registry. *Catheter Cardiovasc Interv* 2015;86(4):728-35. doi: 10.1002/ccd.25838
3. Panaich SS, Arora S, Badheka A, et al. Procedural trends, outcomes, and readmission rates pre-and post-FDA approval for MitraClip from the National Readmission Database (2013-14). *Catheter Cardiovasc Interv* 2017 doi: 10.1002/ccd.27366
4. Boeder NF, Dorr O, Rixe J, et al. Endocarditis after interventional repair of the mitral valve: Review of a dilemma. *Cardiovasc Revasc Med* 2017;18(2):141-44. doi: 10.1016/j.carrev.2016.11.003
5. Russo M, Andreas M, Taramasso M, et al. Prosthetic valve endocarditis involving the MitraClip device. *J Card Surg* 2017;32(11):696-97. doi: 10.1111/jocs.13225
6. Habib G, Lancellotti P, Antunes MJ, et al. 2015 ESC Guidelines for the management of infective endocarditis: The Task Force for the Management of Infective Endocarditis of the European Society of Cardiology (ESC). Endorsed by: European Association for Cardio-Thoracic Surgery (EACTS), the European Association of Nuclear Medicine (EANM). *Eur Heart J* 2015;36(44):3075-128. doi: 10.1093/eurheartj/ehv319
7. Nishimura RA, Otto CM, Bonow RO, et al. 2017 AHA/ACC Focused Update of the 2014 AHA/ACC Guideline for the Management of Patients With Valvular Heart Disease: A Report of the American College of Cardiology/American Heart Association Task Force on Clinical Practice Guidelines. *J Am Coll Cardiol* 2017;70(2):252-89. doi: 10.1016/j.jacc.2017.03.011



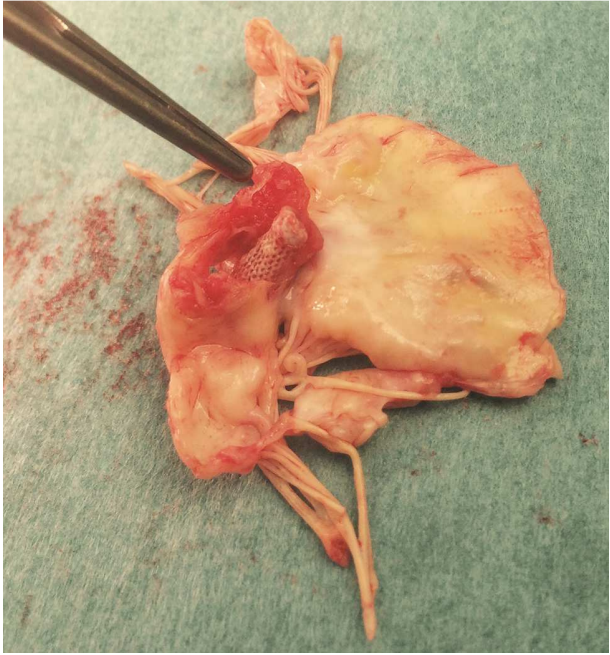**Figure Legends**

**Figure 1.** Echocardiographic pre-operative images. Left image: transthoracic echocardiography, two chamber view showing MitraClip in situ and severe mitral regurgitation. Right image: Transesophageal image, four chamber view showing a large vegetation (2 cm) on the mitral valve.

**Figure 2.** Intraoperatively excised mitral valve with MitraClip in situ. Picture of the en block excised, severely destructed native posterior mitral valve leaflet with remaining MitraClip in situ.



ACCEPTED MANUSCRIPT



ACCEPTED MANUSCRIPT